

# Middle Ear and Inner Ear

Semicircular canals

Utricle

Sacculle

Stapes

Incus

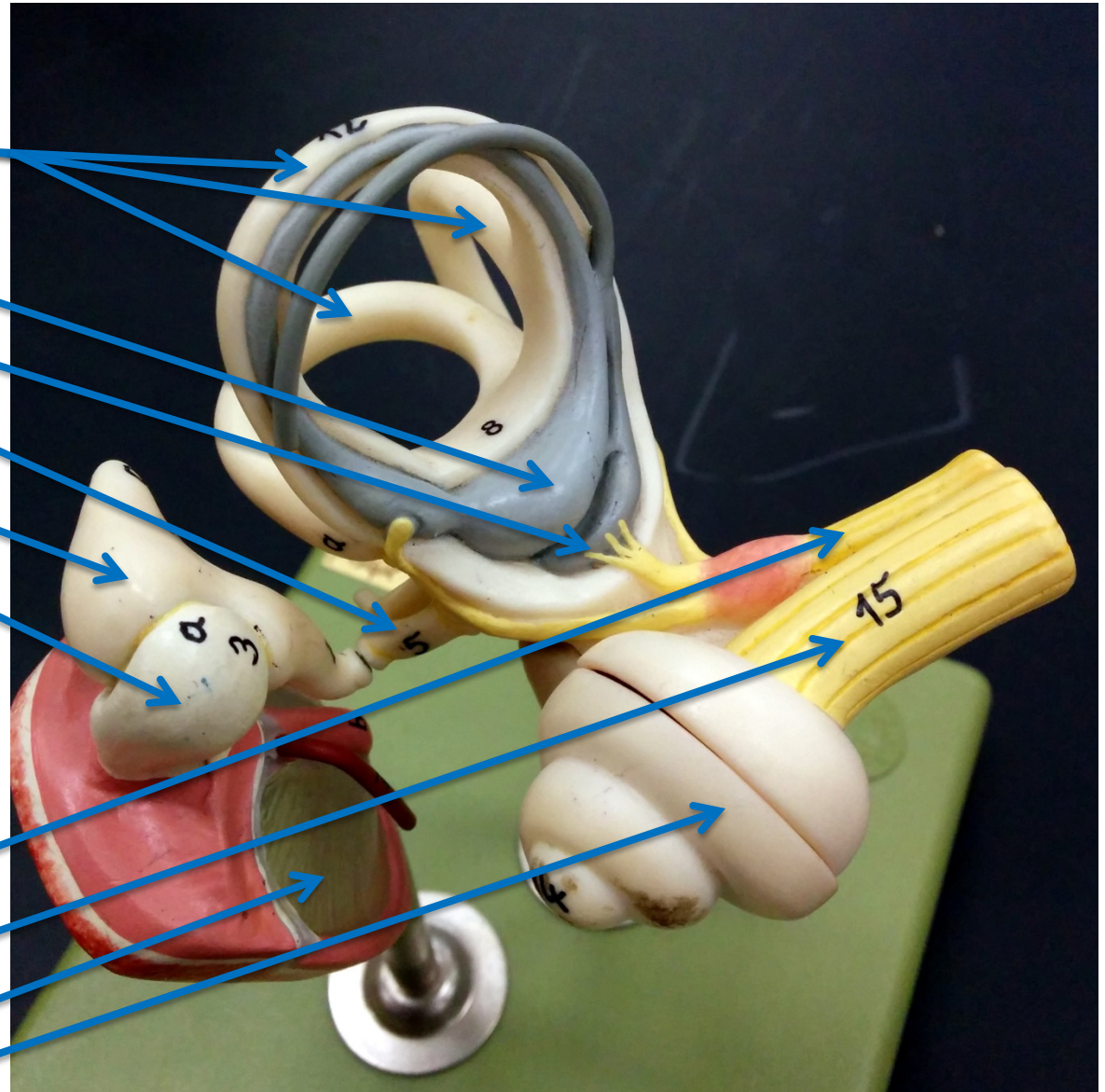
Malleus

Vestibular nerve

Cochlear nerve

Tympanic Membrane

Cochlea



# Inner Ear

Semicircular canals

Vestibule

Ampulla

Oval window

Round window

Cochlea

